

Back: Sacroiliac Joint Fusion or Stabilization

MEDICAL POLICY NUMBER:24

Effective Date: 7/1/2023
Last Review Date: 5/2023
Next Annual Review: 2/2024
COVERAGE CRITERIA 2
POLICY CROSS REFERENCES 4
POLICY GUIDELINES 4
REGULATORY STATUS..... 7
CLINICAL EVIDENCE AND LITERATURE REVIEW..... 11
BILLING GUIDELINES AND CODING 28
REFERENCES 29
POLICY REVISION HISTORY 33

INSTRUCTIONS FOR USE: Company Medical Policies serve as guidance for the administration of plan benefits. Medical policies do not constitute medical advice nor a guarantee of coverage. Company Medical Policies are reviewed annually and are based upon published, peer-reviewed scientific evidence and evidence-based clinical practice guidelines that are available as of the last policy update. The Company reserves the right to determine the application of medical policies and make revisions to medical policies at any time. The scope and availability of all plan benefits are determined in accordance with the applicable coverage agreement. Any conflict or variance between the terms of the coverage agreement and Company Medical Policy will be resolved in favor of the coverage agreement. Coverage decisions are made on the basis of individualized determinations of medical necessity and the experimental or investigational character of the treatment in the individual case. In cases where medical necessity is not established by policy for specific treatment modalities, evidence not previously considered regarding the efficacy of the modality that is presented shall be given consideration to determine if the policy represents current standards of care.

SCOPE: Providence Health Plan, Providence Health Assurance, Providence Plan Partners, and Ayin Health Solutions as applicable (referred to individually as "Company" and collectively as "Companies").

PLAN PRODUCT AND BENEFIT APPLICATION

Commercial

Medicaid/OHP*

Medicare**

*Medicaid/OHP Members

Oregon: Services requested for Oregon Health Plan (OHP) members follow the OHP Prioritized List and Oregon Administrative Rules (OARs) as the primary resource for coverage determinations. Medical policy criteria below may be applied when there are no criteria available in the OARs and the OHP Prioritized List.

**Medicare Members

This Company policy may be applied to Medicare Plan members only when directed by a separate Medicare policy. Note that investigational services are considered “**not medically necessary**” for Medicare members.

COVERAGE CRITERIA

Note: See [Policy Guidelines](#) for definitions of terms in criteria.

Open Sacroiliac Joint Fusion

- I. Open sacroiliac joint fusion with an [FDA-approved fixation device](#) is considered **medically necessary** when **all** of the following criteria (A. – C.) are met:
 - A. Imaging studies demonstrate localized sacroiliac joint pathology for one of the covered indications noted in criterion I.C.; **and**
 - B. The patient is a nonsmoker, or in the absence of progressive neurological compromise will refrain from use of tobacco products for at least 6 weeks prior to the planned surgery. To ensure compliance, laboratory testing may be required at Medical Director discretion; **and**
 - C. Fusion is performed in any one or more of the following circumstances (1.-4.):
 1. As an adjunctive treatment for sacroiliac joint infection or sepsis; **or**
 2. Management of sacral tumor (e.g., partial sacrectomy); **or**
 3. As part of multisegmental long fusion for the correction of a congenital or acquired spinal deformity extending to the ilium (e.g., scoliosis, spondylolysis, kyphosis) (Refer to [Back: Fusion and Decompression Procedures](#) Medical Policy for coverage criteria); **or**
 4. SI joint abnormality with imaging consistent with prior trauma.
- II. Open sacroiliac joint fusion is considered **not medically necessary** when criterion I. above is not met, or as a treatment of any other conditions, including but not limited to:
 - A. Mechanical low back pain
 - B. Sacroiliac joint syndrome

- C. Sacral insufficiency fractures
- D. Degenerative sacroiliac joint
- E. Radicular pain syndromes
- F. Pelvic girdle pain

Percutaneous or Minimally Invasive Sacroiliac Joint Fusion

- III. Percutaneous (also known as minimally invasive) sacroiliac joint fusion (e.g., iFuse Implant System®, SImmetry® System, Silex™) with an [FDA-approved fixation device](#) may be considered **medically necessary** when **all** of the following criteria (A. – H.) are met:
- A. Device is placed across the SI joint (i.e., transfixing device) and intended to promote fusion; **and**
 - B. Clinical documentation that age-appropriate activities of daily living are moderately or severely impacted; **and**
 - C. Symptoms have failed to improve after 6 months conservative treatment (see [Policy Guidelines](#)) as part of pre-operative surgery planning; **and**
 - D. Patient has undergone thorough physical examination demonstrating localized tenderness with palpation over the sacral sulcus (Fortin’s point, i.e. at the insertion of the long dorsal ligament inferior to the posterior superior iliac spine or PSIS) in the absence of tenderness of similar severity elsewhere (e.g. greater trochanter, lumbar spine, coccyx) indicating that other obvious sources for their pain do not exist; **and**
 - E. Patient has a documented positive response to **at least 3** provocative tests (e.g. thigh thrust test, compression test, Gaenslen’s test, distraction test, Patrick’s sign, posterior provocation test); **and**
 - F. There is an absence of generalized pain behavior (e.g. somatoform disorder) and generalized pain disorders (e.g. fibromyalgia); **and**
 - G. Patient undergoes diagnostic imaging that includes **all** of the following (1.-3.):
 1. Imaging (plain radiographs and a CT or MRI) of the SIJ that excludes the presence of destructive lesions (e.g. tumor, infection), fracture, traumatic sacroiliac joint instability, or inflammatory arthropathy; **and**
 2. Imaging of the pelvis (AP plain radiograph) that rules out concomitant hip pathology; **and**
 3. Imaging of the lumbar spine (CT or MRI) to rule out neural compression or other degenerative condition that can be causing low back or buttock pain; **and**
 - H. Patient has undergone 2 separate image-guided, contrast-enhanced intra-articular SIJ injection on 2 separate occasions, of which, one must have been a therapeutic intra-articular SIJ injection (i.e., corticosteroid injection); and had a documented pain reduction of at least 75 percent for the expected duration for the anesthetic used.
- IV. Percutaneous or minimally invasive sacroiliac joint fusion is considered **not medically necessary** when criterion III. as above is not met, including devices which are not intended to transfix the SI joint and promote bone fusion (e.g., LinQ SI Joint Stabilization System).

Link to [Evidence Summary](#)

POLICY CROSS REFERENCES

[Back: Fusion and Decompression Procedures, MP10](#)

The full Company portfolio of current Medical Policies is available online and can be [accessed here](#).

POLICY GUIDELINES

DOCUMENTATION REQUIREMENTS

The following information must be submitted in order to determine if medical necessity criteria are met:

- Indication for the requested surgery
- Clinical notes documenting that the individual has been evaluated at least once by the requesting surgeon before submitting a request for surgery.
- Medical records must document that a detailed examination has been performed by, or reviewed by the operating surgeon, within 3 months prior to surgery.
- Clinical documentation of extent and response to conservative care (see [Policy Guidelines](#) for all requirements), as applicable to the policy criteria, including outcomes of any procedural interventions, medication use and physical therapy notes.
- Evaluation and documentation of the extent and specifics of one or more of the functional impairments or disabilities.
- Evaluation and appropriate management of associated cognitive, behavioral or addiction issues if and when present.
- Copy of radiologist's report(s) for diagnostic imaging (MRIs, CTs, etc.) completed within the past 12 months or at the time of onset of symptoms
 - Imaging must be performed and read by an independent radiologist
 - If discrepancies should arise in the interpretation of the imaging, the radiologist report will supersede

DEFINITIONS

Activities of daily living: The activities of daily living (ADLs) is a term used to describe essential skills that are required to independently care for oneself.¹ Examples may include, but are not limited to, the following:

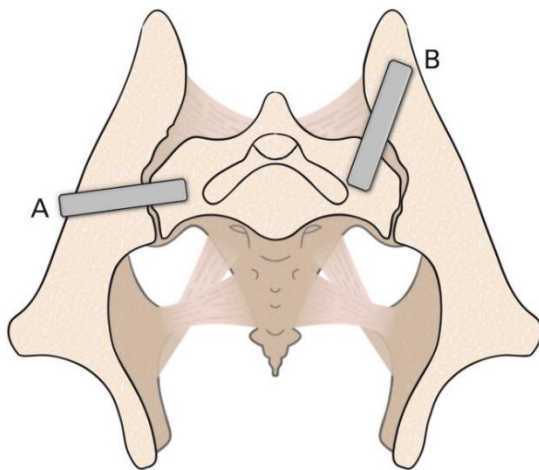
- Ambulating
- Feeding
- Dressing
- Personal hygiene
- Transportation and shopping

- Meal preparation
- Housecleaning and home maintenance

Conservative treatments: Conservative care must be recent (within the last year) and include all of the following, unless contraindicated by documentation indicating severe or rapidly progressive neurologic signs:

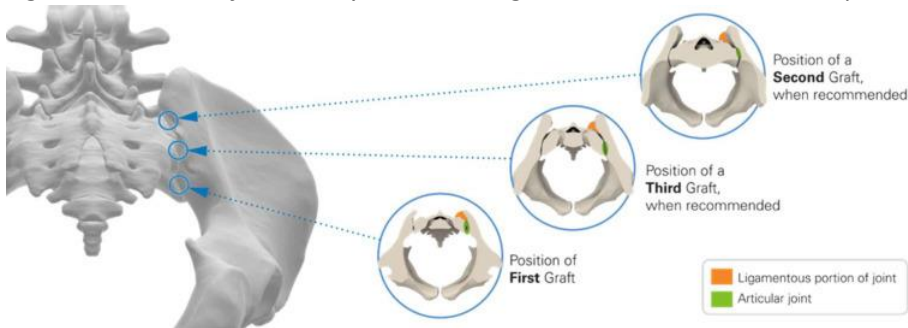
- Participation in a physical therapy program for the duration of conservative management (i.e., 3 months before surgery depending on the indication for surgery), including at least 3 physical therapy visits
- Oral analgesics (including anti-inflammatory medications, if not contraindicated) or participation in an interdisciplinary pain management program
- Oral corticosteroids (if not contraindicated)

Figure 1: Lateral transiliac transfixing devices



(A) Typical lateral transiliac trajectory. (B) Rialto posterolateral transiliac trajectory.²

Figure 2: Position of minimally invasive surgical intraarticular/"dorsal" products:²



BACKGROUND

Conditions

Chronic low back pain (LBP) has many different etiologies, including problems stemming from the sacroiliac (SI) joints. Pain in the lower back triggered from the SI joint occurs in 15% to 30% of patients with LBP. Causes of SI joint pain include, but are not limited to, degenerative sacroiliitis, osteoarthritis, SI joint disruptions from trauma or pregnancy, problems after lumbar spinal fixation techniques, anatomical abnormalities such as scoliosis, infection, gout, tumor or idiopathic causes. In some cases, the cause or source of LBP is unknown, making identification of appropriate treatments difficult.

Treatments

Conditions which cause SI joint pain are typically treated first with conservative measures that may include analgesics, non-steroidal anti-inflammatory drugs, physiotherapy, spinal manipulation, pelvic/sacroiliac belts and external lumbar braces. Additional minimally invasive interventional treatments such as intra-articular or periarticular injections of corticosteroid or anesthetics, botulinum toxin injections and radiofrequency denervation have been proposed, but are not all proven effective in alleviating symptoms.

Surgical Treatment of SI Joint Conditions

SI joint fusion (SIJF) is only recommended as a last resort treatment of specific conditions such as SI joint infection, sacral tumor, lower spinal deformities, or pelvic ring fracture or dislocation. SIJF is not recommended to treat “general SI pain syndrome” due to the following:

- Other spinal structures, such as the posterior facet joints or lumbar discs, may refer pain to the SI joint area, limiting the reliability of SI fusion treatment effect.
- Imaging studies do not demonstrate SI joint abnormalities associated with general pain syndromes, limiting diagnostic and treatment validity.
- There are no standardized diagnostic tests or reference standards with which to measure SI joint pain.
- Pain reduction is a subjective outcome which may be influenced by placebo response or nonspecific treatments not related to SIJF, such as watchful waiting, medication, or physical therapy.

Available SIJF surgical techniques include open, minimally invasive, or percutaneous approaches; however, evidence is limited regarding the efficacy of procedures which do not directly visualize the SI joint (MIS/percutaneous approach). Treatment can be done either uni- or bi-laterally and may be performed simultaneously, or in staged procedures. While some types of implants may be used in more than one surgical technique, newer implants such as the iFuse are intended for minimally invasive or percutaneous approaches only, which do not include direct visualization of the SI joint.

Open SI Joint Fusion

Open surgical techniques involve direct visualization of the sacroiliac joint and may include anterior and posterior approaches that can be performed with and without screws or plates, and a posterior midline fascial splitting approach. Reoperation rates for open SI fusion procedures are highly variable, but have been reported to be between 0% - 65% (mean 15%) in early publications of small case series.³ The wide range may be due to the variety of conditions treated and procedures used in open surgery.

Minimally Invasive and Percutaneous SI Joint Fusion

Minimally invasive surgical (MIS) and percutaneous techniques include smaller incisions than open surgeries. In addition, these techniques do not utilize direct visualization of the joint and are performed with fluoroscopy (indirect visualization) alone. Reoperation rates for percutaneous SI fusion procedures have been reported to be between 0% and 17% (mean 6%), and rates are unknown for MIS techniques.³ Whether reoperation rates vary by device cannot be determined due to the lack of comparative studies and the small number of overall studies on devices other than the iFuse implant system.

There are two surgical approaches that are commonly used for minimally invasive/percutaneous SIJF:

- A lateral transarticular approach, in which devices are placed across the SI joint from lateral to medial. In the lateral approach, the SI joint is accessed laterally through a small incision made in the buttock to access the ilium. A pin is passed through the ilium across the SI joint into the center of the sacrum, avoiding the neural foramen. A drill is used to create a pathway through the ilium to the sacrum. An implant is inserted (with the lateral portion of the implant sitting in the ilium and the medial end in the sacrum), spanning the SI joint. Typically three implants are used per side.
- A posterior approach, in which devices are placed into the ligamentous portion of the joint via dissection of the multifidus muscle and removal of ligaments covering the outer posterior surface of the joint. In the posterior approach, a portion of the interosseous SIJ ligament is sometimes removed.

Of note, the lateral approach is the most commonly used MIS/percutaneous approach, which relies on indirect visualization via interoperative fluoroscopy to guide the procedure. To date, all three major iFuse (SI-Bone) sponsored clinical trials (INSITE, iMIA and SIFI) used the same surgical technique involving the lateral approach.⁴

REGULATORY STATUS

U.S. FOOD AND DRUG ADMINISTRATION (FDA)

Approval or clearance by the Food and Drug Administration (FDA) does not in itself establish medical necessity or serve as a basis for coverage. Therefore, this section is provided for informational purposes only.

There are several devices that have been approved by the U.S. Federal Drug & Administration (FDA) for sacroiliac joint fixation under the 510(k) premarket approval process, whose approval, safety, and

effectiveness are all based off predicate devices. The FDA 510(k) approvals do not indicate the appropriate type of surgical technique (open or minimally invasive/percutaneous) which should be used in conjunction with each device. Therefore, indications for use, as outlined in the table below, are based on the device manufacturer website, including manufacturer reported billing for procedure (if available). The list below is not all-inclusive.

Product code: OUR

Table 1. Examples of FDA-Approved Sacroiliac Joint Fusion/Stabilization Implants

Device & Manufacturer (CPT)	Indications for Use	Contraindications for Use	Implant Type and Surgical Technique
iFuse Implant System ^{®5,6} (SI-Bone) CPT 27279	Intended for sacroiliac joint fusion for conditions including sacroiliac joint dysfunction that is a direct result of sacroiliac joint disruptions and degenerative sacroiliitis. This includes conditions whose symptoms began during pregnancy or in the peripartum period and have persisted postpartum for more than 6 months.	<ul style="list-style-type: none"> • Deformities or anatomic variations that prevent or interfere with iFuse placement. • Tumor of sacral or ilial bone. • Active infection at treatment site. • Unstable fracture of sacrum and or ilium involving the sacroiliac joint. • Allergy to metal components. 	Titanium triangular rod, transfixing device
SImmetry SIJ Fusion System (Zyga Technology Inc.) ^{7,8}	Intended for sacroiliac joint fusion for conditions including sacroiliac joint disruptions and degenerative sacroiliitis.	Not reported on FDA or manufacturer website.	Cannulated screw, transfixing device
Silex SIJ Fusion System ⁹ (X-Spine System Inc./Xtant Medical) CPT Open technique: 27280 Minimally invasive	Intended for sacroiliac joint fusion for conditions including sacroiliac joint disruptions and degenerative sacroiliitis.	Not reported on FDA or manufacturer website.	Cannulated screw, transfixing device

technique: 27279			
SILO TFX MIS Sacroiliac Joint Fixation System (Aurora Spine) CPT Minimally invasive technique: 27279	Intended for sacroiliac joint fusion for conditions including sacroiliac joint disruptions and degenerative sacroiliitis.	Not reported on FDA or manufacturer website.	Cannulated screw, transfixing device
Entasis Dual-Lead SI Implant (Corelink Inc.) ^{10,11}	Intended for sacroiliac joint fusion for conditions including degenerative sacroiliitis and sacroiliac joint disruptions.	Not reported on FDA or manufacturer website.	Cannulated screw
SIMPACT Sacroiliac Joint Compression Screw System ^{12,13} (Life Spine Inc.)	Intended for sacroiliac fusion for the following conditions: <ul style="list-style-type: none"> • Sacroiliac joint dysfunction that is a direct result of sacroiliac joint disruption and degenerative sacroiliitis. This includes conditions whose symptoms began during pregnancy or in the peripartum period and have persisted postpartum for more than 6 months. • To augment immobilization and stabilization of the sacroiliac joint in skeletally mature patients undergoing sacropelvic fixation as part of a lumbar or thoracolumbar fusion. • Acute, non-acute, and non-traumatic fractures 	Not reported on FDA or manufacturer website.	Cannulated screw, transfixing device

	involving the sacroiliac joint.		
Sicage System (Sicage LLC) ^{14,15}	Intended for sacroiliac joint fusion for conditions including sacroiliac joint disruptions and degenerative sacroiliitis.	Not reported on FDA or manufacturer website.	Cannulated screw, transfixing device
RIALTO™ SI Fusion System (Medtronic Sofamor Danek) ^{16,17} CPT 27279	Intended for Sacroiliac Joint fusion for conditions including Sacroiliac Joint disruptions and degenerative sacroiliitis.	<ul style="list-style-type: none"> • Deformities. • Tumor resection. • Infection local to the operative site and/or signs of local inflammation. • Suspected or documented allergy or intolerance to the component materials. 	Cannulated screw, transfixing device
Siconus™ Si Joint Fixation System (Camber Spine Technologies) ^{18,19}	Intended to provide fixation and stabilization of large bones, including the sacrum and ilium. It is intended for use in skeletally mature patients as an adjunct to sacroiliac joint fusion in the treatment of degenerative sacroiliitis, or sacroiliac joint disruptions.	Not reported on FDA or manufacturer website.	Cannulated screw, transfixing device
Firebird SI Fusion System (Orthofix Inc.) ²⁰	Intended for fixation of sacroiliac joint disruptions, and intended for sacroiliac joint fusion for conditions including; <ul style="list-style-type: none"> • sacroiliac joint disruptions, • degenerative sacroiliitis, • to augment immobilization and stabilization of the sacroiliac joint in skeletally mature 	<ul style="list-style-type: none"> • Open wounds, infection, presence of tumor, pregnancy, osteoporosis, certain metabolic disorders affecting osteogenesis, certain inflammatory / neuromuscular conditions, and certain neuromuscular deficits which would place an unusually heavy load on the device during the healing period. 	Cannulated screw, transfixing device

	<p>patients undergoing sacropelvic fixation as part of a lumbar or thoracolumbar fusion and</p> <ul style="list-style-type: none"> ○ Acute, non-acute, and non-traumatic fractures involving the sacroiliac joint 	<ul style="list-style-type: none"> ● The implant is made from Ti-6Al-4V ELI (medical-grade titanium alloy). The fixation implant is contraindicated in any individual with a known or suspected allergy, sensitivity, or intolerance to metal. 	
--	--	---	--

CLINICAL EVIDENCE AND LITERATURE REVIEW

EVIDENCE REVIEW

Evaluating the safety and effectiveness of minimally invasive SIJF with FDA-approved implants requires randomized controlled trials to isolate the treatment effect of SIJF. Randomization is critical in evaluating any intervention in which clinically relevant outcomes consist of subjective, self-reported improvements in pain, function and disability, since these outcomes may be influenced by nonspecific effects like placebo response and the natural history of the disease. As a result, when randomization is used, differences in reported outcomes between treatment groups may be attributed to the treatment in question. In addition, comparative, randomized studies must be sufficiently powered in order to eliminate any spurious results due to chance, and to allow generalizability of results. Ideally, long-term, randomized studies (minimum of five years) are recommended to assess late adverse events, late reoperation rates, and potential sustained benefits.

The review of open SIJF below is limited to systematic reviews and studies addressing investigational indications such as open SIJF to treat general pain not relating to medically necessary indications listed in the Policy Criteria section above. Evidence comparing open to minimally invasive/percutaneous surgeries and minimally invasive/percutaneous vs. non-surgical management was also reviewed.

A review of the ECRI, Hayes, Cochrane, and PubMed databases was conducted regarding the use of sacroiliac joint fusion (SIJF). Below is a summary of the available evidence identified through January 2022.

Of note, the minimally invasive/percutaneous approach is referred to as MIS for the remainder of the policy.

Open Versus MIS SI Joint Fusion to Treat Various Conditions

Systematic Reviews

The following systematic reviews evaluated various open/MIS procedures and device types to treat a wide variety of conditions. In addition, the length of follow-up between open versus MIS groups varied. These heterogeneous factors preclude conclusions regarding the benefits of SI joint MIS surgical techniques compared to open procedures to treat any condition.

- In 2015, Zaidi et al. published a systematic review of the surgical and clinical efficacy of SIJF, including 16 studies (five consecutive case series, eight retrospective studies, and three prospective cohort studies, N=430).³ Seven studies reported on open surgery, eight studies on MIS procedures and one small retrospective study compared the two procedures.²¹ In total, 131 patients underwent open surgery and 299 underwent MIS for SIJF. The patient populations treated using open surgical techniques were different from those being treated using MIS procedures. Patients who underwent open surgery had SI joint pain due to a number of different pathologies including SI joint degeneration/arthrosis, SI joint dysfunction, postpartum instability, posttraumatic, idiopathic, and rheumatoid arthritis. Whereas, the patients undergoing MIS procedures had SI joint pain due to SI joint degeneration/arthrosis, SI joint dysfunction, or pathological fractures. In addition, the studies included on open surgeries all used different surgical techniques and different fusion devices. The mean duration of follow-up was 60 months for open surgery and 21-month follow-up for MIS.

Radiographically confirmed fusion rates were highly variable within and between surgical techniques, with fusion rates ranging between 20%–90% for open surgery and 13%–100% for MIS. However, 80% of the MIS studies did not include image-confirmed anatomical fusion as part of the outcome assessment. Pain reduction, and functional and quality of life improvements ranged from 18% to 100% (mean of 54%) in open surgical cases, and 56% to 100% (mean 84%) in the MIS group. The reoperation rate ranged from 0% to 65% (mean 15%) for open surgery and from 0% to 17% (mean 6%) after MIS. The major complications after open surgery were painful hardware leading to removal (9.9%), deep wound or pin infections (2.2%), and nerve root irritation (1.5%). Major complications encountered after MIS were new-onset facet joint pain (2.7%), trochanteric bursitis (2.3%), deep wound infections (1.7%), new onset of low-back/buttock pain (1.7%), and worsening knee/leg pain (1.7%), with one study reporting a 56% adverse event rate in the MIS group. Of note, statistical analyses were not reported on these outcomes, so it is unclear if the differences in any of the outcomes between procedures are significant. The fact that the MIS patients were followed up for a much shorter time period than the open surgery patients may explain the lower number of major adverse events and revision rates reported in the MIS studies. In addition, the new onset and worsening of pain reported in the MIS group, especially after only 24-months of follow-up may indicate a treatment regression post-procedure for MIS for SIJF. The reviewers stated that “whether efficacy is determined by objective measures, CT-confirmed fusion, or subjective methods, patients’ levels of satisfaction with the results of fusion procedures are inconsistent.” In addition, the reviewers found that confirmed fusion rates, patient satisfaction, and reoperation rates varied greatly within and between surgical techniques. The reviewers concluded that, with evidence of fusion rates and long-term pain control lacking for both open and MIS procedures, additional well-designed long term randomized studies were needed for both open and MIS SIJF to determine the surgical and clinical efficacy.

- In 2016 (updated 2019), ECRI reviewed evidence for iFuse Implant System for minimally invasive SIJF as a treatment for chronic low back pain.²² For iFuse versus open surgery, only one comparative study (n=63) was mentioned; no between-group differences were found. Amongst the eight studies

reporting on 13,201 patients with other comparators (screw-type implants and nonsurgical conservative management), ECRI concluded that the evidence was somewhat favorable. There are significant gaps in the evidence, however, and current ongoing RCTs will not address the outstanding questions. Additional RCTs comparing iFuse with other MIS implants and open surgery, as well as reporting outcomes of two or more years are needed to validate the existing conclusions within the literature.

The report identified four systematic reviews, one RCT, two nonrandomized studies comparing open and MIS, and one retrospective case series. The systematic reviews all included studies that were heterogeneous in terms of the patient populations and surgical techniques used. The primary literature included patients diagnosed with SI joint disruption, sacroiliitis or pelvic girdle pain. Based on the heterogeneous evidence identified, the report indicated that estimated blood loss, length of surgery, and length of hospitalization was significantly lower for MIS compared to open surgery. However, it was unclear from the included studies of MIS if fusion of the joint had occurred based on the imaging techniques employed. The review concluded that fusion surgery, in general, may work for reducing pain in patients with chronic low back pain of various etiologies; however, the beneficial effects may diminish over time. Longer follow-up and evaluation of outcomes were recommended.

Randomized Controlled Trials (RCTs)

Since the publication of the systematic reviews noted above, no RCTs were identified that compared the safety and effectiveness of open SIFJ to any minimally invasive treatments.

Nonrandomized Comparative Studies

- In 2013 Smith, et al. published the results of an industry-affiliated, multi-center, retrospective comparative cohort study that compared perioperative measures and clinical outcomes of patients with SI joint disorders who underwent SIFJ using either an open surgical (OS) or a minimally invasive surgical (MIS) technique.²³ All patients were diagnosed with SI joint disorders using a combination of detailed history, clinical exam, imaging and diagnostic injections. The open technique used a combination of screws and cages while the MIS technique, performed laterally, employed a series of the iFuse implants. Data on 263 patients treated by seven surgeons was used for the analysis (149 patients treated with OS and 114 treated with MIS SIFJ). Compared to OS patients, MIS patients were on average 11 years older and the majority were female, compared to the open patients. MIS operating time and length of hospitalization were significantly lower than open surgery ($p < 0.001$). Postoperative pain scores were on average 3.0 points (95% CI 2.1 – 4.0) lower in MIS group compared to the OS group ($p < 0.001$). At 12-month follow-up, the MIS patients had decreases in pain level from baseline pain relief that were significantly greater than the open patients (-6.2 vs. -2.7 points; $p < 0.001$). Postoperative complications were slightly more common in the open surgery group (21% of patients) compared to the MIS group (18%), but significance was not reported. Sources of surgical revisions including pseudoarthrosis, screw loosening, and spinal implant irritation were present (43%) in the open surgery cohort but not the MIS group. However, revisions (3.5%) in the MIS group were the result of suboptimal implant placement. The authors noted that a number of the sites included in this study provided incomplete data on one or more outcomes. Outcomes of this analysis are difficult to interpret since patients in both treatment groups were heterogeneous in

terms of the underlying cause of SI joint pain, prior surgical treatments, and whether they had unilateral or bi-lateral procedures.

- In 2014, Ledonio et al. published two small retrospective chart reviews that compared safety and efficacy of open versus minimally invasive SIJF using the iFuse device, assessing patients at a minimum of 12-months post-procedure.^{21,24} One chart review assessed patients from a single-center (Minneapolis),²¹ while the other from two sites (Minneapolis and Indiana), that appear to have largely overlapping cohorts. In the larger of the two reviews, 22 patients were assessed that had undergone open surgery and 22 with MIS with the iFuse, and these patients were matched for a number of confounding variables.²¹ Both studies only included patients diagnosed with SI joint disruption or degenerative sacroiliitis, and both studies performed the MIS using the lateral technique. In the larger study, estimated mean blood loss was lower in the MIS group than open (681 mL versus 41 mL, $p < 0.001$). In addition, mean surgical time and LOS were shorter in the MIS group than in the open group (68 minutes versus 128 minutes and 3.3 days versus 2 days, $p < 0.001$). However, mean postoperative self-reported Oswestry Disability Index (ODI) disability scores for the open and MIS groups were not significantly different ($47\% \pm 22\%$ and $54\% \pm 17\%$, respectively; $p = 0.272$). The ODI improved in 15 of 22 (68%) patients in the open group, with a mean improvement of 19.8 points from baseline, and in 16 of 22 (73%) in the MIS group, with a mean improvement of 12 points from baseline. The improvement was significant ($p < 0.001$) for both groups. Adverse event rate and revision rate was the same for each treatment group (13%). In contrast, in the smaller two-center study, the authors reported that the MIS group has significantly improved ODI compared to the open group (42% change from baseline for MIS versus 9% change in open, $p < 0.0008$). However, the smaller two-center study had slightly different inclusion criteria (minimal pre-operative ODI score), did not match the patients in each group for confounders, did not adjust for confounders in the analysis, and used different statistical tests for analysis (Mann-Whitney U test versus Student's T-test). These methodological differences in patient selection and analysis are likely to have influenced the outcomes of the analysis.

SI Joint Fusion to Treat Generalized Pain Syndrome

Systematic Reviews

- In 2016, Lingutla et al. published the results of a poor- to moderate quality systematic review designed to determine whether SIJF was effective in reducing SI joint pain, including only six observational studies with a mean follow-up of 17.6 months.²⁵ Three of the studies used similar minimally invasive surgical (MIS) techniques to implant the iFuse device, while two used open procedures to implant hollow modular anchorage screws, and one study was a comparative study of open and MIS. Of note, the three MIS studies and the comparative study included patients diagnosed with SI joint disruption or sacroiliitis, but the two open studies included patients with general SI joint disease not related to any specific etiology. All analyses were pooled in terms of the technique used, despite the fact that the three open surgery studies used different devices and included different patient populations. No comparisons between open and MIS were reported in this review. In a meta-analysis combining both open and MIS studies, mean visual analog scale (VAS) pain difference between baseline and follow-up (three studies, range 6-60 months) was reported as 54.8 (95 % CI 48.6, 61.0; $n = 380$; $p < 0.001$), while the ODI mean difference between baseline and post-procedure was 14.5 (95 % CI 8.4, 20.6; $n = 102$; $p < 0.001$). Other self-reported outcomes of statistical improvement post-procedure included: SF-36 PCS mean difference of -19.5 (95 % CI -24.7,

-14.2; n = 140; p < 0.001), SF-36 MCS mean difference of -8.5 (95 % CI -12.9, -4.1; n = 198; p < 0.001) and Majeed score mean difference of -35.4 (95 % CI -48.5, -22.2; n = 140; p < 0.001). The reviewers concluded that although SIJF, in general, appears to be a satisfactory procedure for alleviating low back pain, but further high-quality studies were needed. Limitations of this review include different patient populations within the included open studies and between open and MIS studies, different procedures and devices used within the open studies and between the open and MIS studies, and highly heterogeneous follow-up times for all included studies (range 6-60 months for MIS and 9-84 months for open).

- In 2017 (archived 2020), Hayes published a review of open SIJF for SIJ dysfunction not relating to medically necessary indications like acute trauma, fracture, dislocation, tumor, infection, spinal deformity.²⁶ The only studies identified that compared open SIJF to MIS, were two studies that used MIS to implant the iFuse device, and these studies by Smith et al. and Ledonio et al. are described in detail above.^{21,23,24} The results of a small, poor quality retrospective pretest/posttest study reported significant improvement of several subjective patient-reported outcomes at last follow-up (n=15 patients at a mean of 5.8 years post-open surgery). A small, poor quality nested case-control study reported that improvement on the ODI scale at 12 months was clinically and statistically significant in all 44 patients who underwent open surgery (p=0.007). Of note, one of the two retrospective studies that reported on reoperation rates indicated that during a mean follow-up of 39 months, 11/17 (65%) of patients underwent additional surgery. Ten of these patients required removal of hardware due to persistent related pain. The other small noncomparative study of 15 patients reported revision rate of 20% (3 patients of 15). All studies identified were determined to be of poor quality. Limitations of studies included observational study designs, retrospective data collection, potential for selection bias, high attrition, inconsistent and limited reporting of statistical analyses, lack of active comparators, and small sample sizes. In addition, short-term follow-up of ≤ 24 months in the majority of studies precluded identification of late adverse events, late reoperation rates and potential sustained benefits of open SI joint surgery.

Noncomparative Studies

- In 2008, Wise and Dall published the results of a small prospective cohort study (n=13 patients) that evaluated the effectiveness of a SI stabilization device comprised of a threaded titanium fusion cages filled with INFUSE/rhBMP-2 (Medtronic) longitudinally inserted percutaneously into the SI joint using the posterior approach and indirect fluoroscopic guidance only through a 5cm-long incision.²⁷ All 13 patients were determined to have refractory SI joint pain of six months or greater. Six patients had bilateral fusions and mean follow-up was 29.5 months (range 24- 35). At six months' post-procedure, computed tomography scan indicated that overall fusion rate was 89% (17/19 joints). At final follow-up significant improvements were seen in the LBP VAS, with an average improvement of 4.9 points (p =0.001). Leg pain improved an average of 2.4 points on the VAS scale (p=0.013). Dyspareunia improved an average of 2.6 points (p=0.0028).
- In 2012, McGuire et al. published the results of a retrospective case series that evaluated the effectiveness of a SIJF technique implanting non-FDA approved fibular allograft dowels using a posterior insertion approach in 37 patients with low back pain attributed to SI joint pain.²⁸ The fusion procedure consisted of minimal muscle stripping over the posterior SIJ and insertion of a cranial and caudal fibular dowel graft across the joint following placement of Steinmann pins. Patients were followed for a mean of 52 months' follow-up (range, 24–62 months). At 6-month

follow-up, 34 patients reported substantial improvement in VAS pain scores (9.1 to 3.4; $p < 0.001$), and improvement in VAS was sustained through subsequent follow-up. Nonunion occurred in four patients with SIJ (10.5%), each of which was successfully treated by secondary autogenous bone grafting and compression screw fixation. It was not clear if an open or MIS approach was used.

- In 2013, Endres and Ludwig, published the results of a small retrospective case series that evaluated the effectiveness of a SI stabilization device called the DIANA cage (which is not currently approved for use in the U.S. by the FDA) including 19 patients with SI joint arthralgia after multi-level lumbar or lumbosacral fusion procedures.²⁹ The DIANA cage was longitudinally inserted percutaneously using the posterior approach and indirect fluoroscopic guidance only through a 4-6cm-long incision. The mean follow-up was 13.2 months. The overall fusion rate was 78.9% (15/19 joints). The mean VAS scores were 8.5 before surgery and 6.0 at final follow-up, demonstrating a 30% improvement ($p = 0.0001$). However, the reduction in ODI score was not significant (64.1 to 56.97), demonstrating a 12% improvement ($p = 0.1887$). Similar improvements in 12-month self-reported VAS and ODI pain scores were also reported in a recent prospective multi-center cohort study of 171 patients with chronic joint pain who underwent indirect implantation of the DIANA cage.³⁰ However, in the latter study, only 31% of patients showed SI joint fusion by CT scan.
- In 2013, Mason et al. published the results of a retrospective case series that evaluated the effectiveness of a SI joint lateral fusion percutaneous technique with indirect visualization using titanium hollow modular anchorage (HMA) screws filled with demineralized bone matrix (which is not currently approved for use in the U.S. by the FDA) including 55 patients with chronic SI joint pain.³¹ The average follow-up period was 36 months (range 12–84). Mean VAS pain scores were reduced from 8.1 to 4.5 ($p < 0.001$). Similar results for these devices were also reported in smaller retrospective case series by Al-Kayer et al. ($n=9$) and Khurana et al. ($n=15$).^{32,33} All three case series only reported on self-reported pain and disability scores, generally reporting improvements in pain and function post-implant. However, none of the studies reported on fusion success.
- In 2016, Kube and Muir published one-year clinical and radiological results from a small cohort study that evaluated the efficacy of the two-screw SImmetry® Sacroiliac Joint Fusion System (Zyga Technologies) in 18 patients with chronic refractory SI joint pain.³⁴ The SImmetry® implants were longitudinally inserted percutaneously using the lateral approach and indirect fluoroscopic guidance only through a 2cm-long incision. At 12 months, the overall fusion rate was 88%, as evaluated by CT. Back and leg pain improved from 81.7 to 44.1 points on the VAS scale ($p < 0.001$) and from 63.6 to 27.7 points ($p = 0.001$), respectively. Disability scores improved from 61.0 to 40.5 ($p = 0.009$). At 12-months, eight patients (50%) achieved the minimal clinically important difference (MCID, VAS reduction of 20 points) in back pain, nine (69%) patients achieved the MCID in leg pain and 8 (57%) achieved the MCID in ODI scores (15-point reduction). No major complications were reported.

Key studies from the systematic reviews are described below:

- In 2005, Buchowski et al. published the results of a small ($n=20$) poor-quality, retrospective, pretest/posttest study that evaluated open SIJF for the treatment of SIJ disorders in patients who had failed conservative treatment.³⁵ The most common diagnosis was SI joint dysfunction (13 patients, 65%), followed by SI joint osteoarthritis (5 patients, 25%). One patient had inflammatory arthritis, and one had postpartum instability. Evidence of fusion was seen on plain radiographs in 17 of 20 patients (85%) within one year of surgery, for an overall fusion rate of 85%. Only 15 patients

(75%) were willing to be included in the follow-up analysis (mean follow-up of 5.8 years). The authors reported that nine patients (60%) reported significant improvement in outcomes at last follow-up. However, postoperative changes in general health, mental health, or comorbidity scores were not statistically significant. Surgical complications included nonunions that required revision surgery in 15% (3 out of 20), deep wound infection in 10%, and complaint of painful hardware by one patient. Study limitations include small sample size, heterogeneous patient population, observational study design, retrospective data collection, and high rate of loss to follow-up.

- In 2006, Schütz and Grob published the results of a small (n=17) retrospective case series that evaluated the clinical and radiological outcomes of bilateral SIJ fusion in patients with degenerative SIJ syndrome.³⁶ SIJF was performed using a posterior technique and patients were followed up at a mean of 39 months. At that follow-up, only three patients reported moderate or absent pain, while eight still reported marked pain and six reported severe pain. Seven patients showed symptomatic non-union; and only six patients showed union. Overall, 82% of patients reported that the results were not acceptable. Reoperation was performed in 11 (65%) of the patients. In 10 (59%) patients, the hardware had to be removed due to persistent related pain. The authors concluded that the results were disappointing, and noted that limitations included patient selection, surgical technique, and poor diagnostic procedures.
- In 2014, Kibsgård et al. published the results of a small case series that evaluated physical function and pain after open unilateral anterior sacroiliac joint fusion and fusion of the pubic symphysis for nine patients with severe pelvic girdle pain.³⁷ At 12-months post-procedure, eight patients were available for analysis. Significant reductions were reported in ODI (54 to 37) and VAS (82 to 57) scores ($p < 0.001$), and only two continued to experience pain in the fused joint. However, six patients reported discomfort in the contralateral side. Three major long-term complications were reported: infection, complex regional pain syndrome and loss of bladder sensation. All participants reported high levels of postoperative pain and required epidural treatment for 5-7 days' post-procedure.
- In 2015, Beck et al. published the results of a small (n=20, 33 joints) retrospective case series that evaluated outcomes in patients with symptomatic SI joint pain, who underwent open posterior SIJF using a threaded titanium cage containing rhBMP-2.³⁸ Patients were treated with two mini open arthrodesis techniques. Initially, a posterior medial oblique approach was used, which was then modified to a direct transclef approach. During a mean follow-up of 28.5 months (range, 17-45), no reoperations were reported. At follow-up, 32/33 joints (97%) showed radiographical evidence of successful fusion. However, the authors were unable to report the results of any of the patient-reported outcomes assessed by three different indexes. The authors conceded that the data provided by the patients led to a skewed correlation between two indices used, and that the ODI scale was not of use because it had not been administered pre-operatively.

MIS SI Joint Fusion

MIS SI Joint Fusion versus Non-Surgical Management (NSM)

Systematic Reviews

- In 2019, Tran and colleagues conducted a systematic review and meta-analysis comparing the safety and efficacy of minimally invasive sacroiliac joint fusion to screw-type surgeries.³⁹ Independent investigators systematically searched the literature through December 2017, identified eligible studies, assessed study quality, extracted data and pooled results. In total, 20 studies were included for review. Sample size in the iFuse group ranged from 10 to 172, with a median sample size of 60. The screw-type group had a median sample size of 20, ranging from 6 to 149. Follow-up ranged from 2 weeks to over 3 years. Follow-up ranged from 2 weeks to 3 years. Primary outcomes of interest included pain, disability/physical function, and global/quality of life. Compared to patients receiving screw-type surgeries, iFuse patients experienced statistically significant improvements in pain (SMD = 2.04 [95%CI: 1.76 to 2.33] vs. 1.28 [95%CI: 0.47 to 2.09]), disability (SMD = 1.68 [95%CI: 1.43 to 1.94] vs. 0.26 [95%CI: -1.90 to 2.41]), and global/quality of life (SMD = 0.99 [95%CI: 0.75 to 1.24] vs. 0.60 [95%CI: 0.33 to 0.88]). A significant correlation was also noted between baseline disability and pain levels with post-treatment outcomes. The overall quality of evidence was assessed as “low,” as none of the 4 RCTs investigating iFuse included a placebo or a sham treatment group. Studies were also limited by the lack of comparative data, heterogeneity in patient populations and treatment parameters, inadequate follow-up and manufacturer funding. The systematic review/meta-analysis was itself funded by the manufacturer of iFuse. Despite positive findings, investigators concluded that additional RCTs with long-term follow-up were necessary to further establish the treatment’s safety and efficacy.
- In 2021, the Washington State Health Care Authority updated a systematic review of evidence evaluating the safety and efficacy of sacroiliac joint fusion for the treatment of SI joint pain or dysfunction.^{40,41} Independent investigators systematically searched the literature through January 2021, identified eligible studies, assessed study quality, extracted data and pooled results. In total, 57 studies were included for review (including 2 RCTs and 7 controlled cohort studies). Outcomes of interest included pain, physical function, adverse events and revision surgery. Three studies compared minimally invasive SI joint fusion surgery using iFuse to conservative managements. Patients receiving iFuse experienced significant improvements in pain and disability at 6 months and 3.5-years’ follow-up. One study compared open fusion to no surgery at 11 to 32 years’ follow-up and observed no difference in pain, physical function, or quality of life. Three studies compared iFuse to open fusion, reporting large improvements among iFuse patients in pain at 2-year follow-up, but with mixed findings for patients’ disability/physical function. Limitations included the lack of controlled studies, small sample sizes, lack of intention-to-treat analyses and potential selection bias due of substantial attrition. Based on low-quality evidence, investigators concluded that minimally invasive SI joint fusion surgery with iFuse appeared to be more effective than conservative management for reducing pain and improving function among patients meeting diagnostic criteria for SI joint pain or dysfunction and who have not responded adequately to conservative care. iFuse was also judged to be more effective than open fusion for reducing pain.⁴⁰
- In 2017 (archived 2020), Hayes reviewed the iFuse device for SIJF for treatment of SI joint dysfunction, including six clinical studies (n=61-312 patients), three of which compared iFuse implantation with NSM.²⁶ The studies included two cross over RCTs reporting on short-term outcomes (two years or less), and one nonrandomized study described below reporting on longer-term outcomes, but in a very small patient cohort.⁴²⁻⁴⁴ Only two of the three studies provided comparative analysis of MIS compared with NSM, and these studies suggested that there were greater improvements in self-reported ODI disability scores for the MIS group. The body of evidence was determined to be of low quality, due to the limited number of studies comparing MIS to NSM,

the individual study limitations, and the limited quantity of evidence for any single outcome. According to the Hayes review, limitations of the individual studies included “small sample sizes, lack of outcome assessor blinding, lack of power analyses, limited follow-up, inconsistent reporting of outcomes and statistical analysis, and potential reporting bias due to study funding by and/or author affiliation with SI-Bone Inc. Additional limitations for the observational studies include nonrandomized retrospective study design, high potential for selection bias, and noncontemporaneous comparators.”

- In 2016 (updated 2019), ECRI reviewed the iFuse implant system for minimally invasive SIJF,²² including 19 publications (notably one systematic review, one meta-analysis that included three studies, the same two crossover RCTs^{43,45} reporting on short-term outcomes included in the Hayes review above, and two large nonrandomized cohort studies [n=5319 and 11,416]).⁴⁶ The review stated that the iFuse implant system appears to improve subjective, self-reported pain and disability scores compared with NSM, and that follow-up data indicated that results appeared to be sustained, weakly concluding that the evidence was “somewhat favorable”. However, the review noted that the available evidence provided limited comparisons to alternative treatment methods [such as radiofrequency neurotomy/ablation, or epidural steroid injections] other than conservative management, and that there were evidence gaps that need to be addressed in order to determine the safety and effectiveness of the iFuse. Of note, only one small case series reported long-term evidence on efficacy and adverse events and all but two (of the 19) included studies were nonrandomized and or noncomparative, precluding conclusions regarding the efficacy of MIS surgical management compared to conservative treatments.

Randomized Controlled Trials (RCTs)

- In 2018, Darr and colleagues published results at 4-year follow-up from two prospective clinical trials assessing sacroiliac joint fusion with iFuse across 103 subjects were treated across 12 centers.⁴⁷ Compared to baseline, results indicated improvement in patients’ pain, disability and quality of life scores among the 91 subjects [88.3%] available at follow-up. Between years 3 and 4, 114 adverse events were reported across 75 patients (78%), although none of these were rated as severe. Limitations include substantial loss to follow-up, potential for selection bias (only 12 of the original 39 participating sites qualified to conduct the long-term extension study) and the lack of data on patients who received non-surgical management. Participants in the long-term sites also experienced different numbers of implants and had larger improvements in pain and disability compared to subjects who did not participate in the long-term extension study. Investigators concluded that iFuse provided clinically significant improvements in patients’ pain, functionality, and quality of life.
- In 2016, Polly et al. published two-year outcomes from an industry sponsored RCT of minimally invasive SIJF compared to non-surgical management for SI joint dysfunction, called the Investigation of Sacroiliac Fusion Treatment (INSITE) trial.⁴³ Patients were included if they had a confirmed diagnosis of unilateral or bilateral SIJ dysfunction due to degenerative sacroiliitis and/or sacroiliac joint disruption established from historical findings, SIJ pain elicited on at least three established physical examination provocative tests, and confirmation with at least a 50% decrease in SIJ pain after image-guided SI joint block. This publication was an extension of the 6-month and 12-month outcomes of previous publications.^{48,49} Of the 159 patients enrolled, the trial randomized 148 patients with SIJ dysfunction to minimally invasive SIJ fusion with iFuse triangular titanium implants

(SIJF, n = 102) or non-surgical management (NSM, n = 46). Patients were included if they had a confirmed diagnosis of unilateral or bilateral SI joint dysfunction due to degenerative sacroiliitis and/or SI joint disruption. The implants were placed under guidance from either 2D fluoroscopy (17 sites) or 3D CT (2 sites), using a lateral approach, as published in the original publication of this technique.⁴ Crossover from non-surgical to surgical care was permitted after the 6-month study visit was complete, and 35 of the 46 patients in the non-surgical group crossed over at this time, leaving only nine patients in the NSM group. As reported in the previous study, six-month changes in pain improvement were significantly higher in the SIJF group (mean of 55.4 points) than in the NSM group (12.2 points, $p < .0001$), and success rates were higher in the SIJF (81.4% vs 26.1%).⁴⁸ By month 24, 82.0% reported substantial reductions in the VAS SIJ pain score, indicating sustained pain relief in the SIJF group. Similarly, 65.9% reported substantial clinical benefit (assessed by ODI score). In the NSM group, these proportions were <10% with non-surgical treatment only.

A total of 22 (23%) adverse events related to device or procedure occurred in the SIJF group, including ipsilateral or contralateral SI joint pain and trochanteric bursitis (n=9), surgical wound problems (n=5), postoperative medical problems (n=4, including nausea/vomiting, urinary retention, and atrial fibrillation), iliac fracture (n=1), asymptomatic physical exam or radiographic findings (n=2), and neuropathic symptoms (n=1). In addition, three patients in the SIJF group and one patient who had received treatment after crossover, required revision surgery within the 24-month follow-up period.

Apart from the limitations noted above, additional limitations of this trial include lack of blinding, and that the 12- to 24- month analyses of certain outcomes for the NSM group included the 35 patients who had crossed over to the treatment group, making it difficult to make meaningful comparisons. In addition, in the SIJF group, 13 subjects (13%) withdrew prior to month 24 and 9 (9%) were lost to follow up, indicating a high drop-out rate. Lastly, the implant surgeries were performed across 19 centers within the U.S., conceivably leading to heterogeneity between study sites, which is not accounted for in the analyses.

- In 2017, Stuesson et al. published six-month outcomes from the iFuse Minimally Invasive Arthrodesis (iMIA) RCT that compared the safety and effectiveness of minimally invasive SIJF using iFuse implants to conservative management (CM) in patients with chronic SIJ pain.⁴⁵ The trial included 103 adults with chronic SIJ pain at nine sites in four European countries, of which 52 patients were assigned to the minimally invasive SIJF using iFuse implants inserted laterally, while 51 patients were assigned to the CM group. At six months, mean low back pain, as measured by the self-reported LBP VAS, had improved significantly from baseline in the iFuse group (mean improvement of 43.3 points, $p < 0.0001$) but not the CM group (mean SD improvement of 5.7 points, $p = 0.1105$). In addition, the difference in VAS LBP improvement, adjusted by condition, was 38.1 points (difference of 38.1 points, $p < 0.0001$). Self-reported disability, as measured by ODI, showed improvements of by 26 points in the SIJF group and 6 points in the CM group ($p < 0.0001$). Of note, this study did not directly compare any of the outcomes between groups. The frequency of adverse events did not differ between groups. The patient population as a whole was heterogeneous in terms of age, having undergone prior spinal surgeries or other interventions, smoking status, and the underlying etiology of their SI pain. The investigators noted that they did not exclude patients with other contributory sources of LBP (e.g., facet arthropathy or degenerative disc disease) from their patient cohort. The authors also noted that non-surgical care provided to patients in the CM

group varied across centers, which could have impacted the outcomes of patients in the control group.

- In 2017, Dengler et al. published one-year outcomes from the iMIA study described above.⁴² Crossover from non-surgical to surgical care was permitted after the six-month study visit was complete, and 21 of the 49 patients in the non-surgical group crossed over at this time. Due to the crossover to surgical treatment, the authors were unable to assess 12-month responses to CM alone, and as a result, used imputation to estimate 12-month values for CM. The authors reported that at 12 months, outcomes improved significantly in the SIJF group compared to the estimated outcomes in the CM group, based on self-reported VAS pain and ODI disability scores ($p < 0.0001$ for both indices). Of note, the authors also reported that 27% of CM patients did not crossover but achieved threshold improvements in LBP by 12 months, suggesting that that some patients do benefit from physiotherapy. Apart from the limitations described in the previous six-month publication of the iMIA trial by Stuesson et al. described above, additional limitations of this publication include the use of imputation of the estimated pain scores for CM compared to actual pain scores for MIS, and differences in the number of patients lost to follow-up for each treatment group (3 lost in the MIS group versus 7 lost in the CM group at 12-months). Due to the imputed CM outcomes and lack of long-term follow-up to determine late revision rates, the results should be interpreted with caution.

Nonrandomized Comparative Studies

- In 2017, Vanaclocha et al. published an independent retrospective case series comparing six-year outcomes for minimally invasive SI fusion, radiofrequency denervation, and conservative management for SI joint pain of varying etiologies.⁴⁴ This study included 137 patients with SIJ pain seen in an outpatient neurosurgery clinic in Spain who received either conservative management (CM) ($n = 63$), SI denervation ($n = 47$), or minimally invasive SIJF ($n = 27$), and was an extension of the group's prior report on 24 patients in 2014.⁵⁰ In the CM group, 63 patients had 1-yr follow-up, and 2-, 3-, 4-, 5-, and 6-yr follow-up was available in 52, 43, 34, 23, and 16 patients, respectively. In the SIJF group, 27 patients had 1-year follow-up and further follow-up was available in 24, 20, 15, 6, and 1 patients. Mean follow-up time in the CM and SIJF groups was 44 and 41 months, respectively. The authors reported that patients treated with CM had no long-term improvement in pain or disability (as evidenced by their ODI scores, which worsened by 1-6 points), increased their use of opioids, and had poor long-term work status. Despite not being sufficiently powered at the latest time points to assess outcomes from minimally invasive SIJF, the authors reported that these patients had large improvements in SIJ pain (mean ODI score improvement by 6 points) and disability (mean 25 points), a decrease in opioid use, and good final work status. SI denervation patients had intermediate responses for all measures. Of note, the authors stated that patients in the CM group had some demographic and clinical factors that were different from those treated with SIJF, thereby limiting the conclusions that can be drawn. One limitation of this study include the lack of information on the underlying etiology for the diagnosis of SI joint pain, which could be a source of between- and within-group patient heterogeneity. In addition, at five- and six-year follow-up, the SIJF group only consisted of six patients and one patient, respectively, making long-term efficacy and comparisons between groups inaccurate at these later time points.

There are additional, smaller studies on the same cohorts described above that have reported that minimally invasive SIJF with iFuse implants may provide greater pain relief, greater reduction in

disability, patient function and quality of life compared to conservative care and non-surgical management. However, these studies suffer from the same limitations as the studies described in detail above in that they are all nonrandomized studies reporting on subjective, self-reported pain and disability outcomes, and no reporting of actual physiological fusion rates. Furthermore, there is a paucity of well-designed, long-term, randomized controlled trials comparing minimally invasive SIJ techniques. Trials comparing these two techniques are required in order to evaluate the safety and long-term efficacy of a minimally invasive approach.

MIS SI Joint Fusion Treatment Various Conditions (Including Generalized Pain Syndrome)

Systematic Review

- In 2022, Hayes published a health technology assessment on minimally invasive SIJF using triangular titanium implants (iFuse Implant System, SI-Bone Inc).⁵¹ The review identified 11 studies (7 comparative and 4 single-arm clinical studies (n=61-312 [10 studies]; n=11,388 [1 study]), with results published in 20 articles, that evaluated minimally invasive SIJ fusion with the iFuse implant for treating pain related to SIJ dysfunction. The evidence base included 2 randomized controlled trials (RCTs), 5 retrospective comparative cohort studies, 1 retrospective uncontrolled database study, 2 prospective pretest/posttest studies, and 1 retrospective pretest/posttest study. iFuse improved pain and reduced disability across studies, comparing to other surgical treatments and non-surgical management. Hayes found that the overall quality of evidence was moderate. They concluded that “There is moderate-quality evidence suggesting that minimally invasive SIJ fusion with the iFuse Implant System is efficacious for adult patients with SIJ dysfunction that is unresponsive to NSM. iFuse implants are consistently associated with improved pain and disability from baseline without substantial safety concerns.

“The evidence suggests that minimally invasive surgery with the iFuse implant system is more effective than NSM for reducing pain and disability (3 studies: 2 fair quality and 1 poor quality) in patients with symptoms refractory to NSM. Evidence demonstrating superiority of iFuse over NSM suggests that minimally invasive surgery may be a reasonable option for patients with persistent, symptomatic SIJ dysfunction. A limited number of poor-quality and very-poor-quality studies compared iFuse with active treatments other than NSM; 2 poor-quality studies provided comparisons with open surgery, 1 poor-quality study compared iFuse with denervation, 1 poor-quality study compared iFuse with minimally invasive SIJ fusion using a CTI, and 1 very-poor-quality study provided a comparison with screw fixation and only evaluated revision rates. This limited evidence suggests that the iFuse implant is at least as effective as alternative surgical approaches. Additional well-designed studies are needed to evaluate longer-term outcomes, determine optimal patient selection criteria, and define appropriate diagnostic techniques.”

Hayes gave iFuse a B rating for minimally invasive SIJF in adults with SIJ dysfunction refractory to nonsurgical management.

- In 2015, Heiney et al. published the results of an industry sponsored systematic review that summarized the operative measures and clinical outcomes of minimally invasive SIJF utilizing two different devices, including 18 articles on 12 cohorts from four countries (N=432).⁵² Three studies evaluated insertion of a single hollow modular anchorage (HMA) screw packed with demineralized bone matrix and 15 studies described the placement of a series (typically three, range 2-4) of iFuse

implants, with significant overlap in studies included in the Zaidi review described above.³ Mean baseline self-reported pain scores were 8.1, six-month scores were a mean of 2.8, 12-month scores dropped to 2.7 and the 24-month score dropped to 2.0. However, the 24-month scores represented the iFuse device only. ODI disability scores decreased by 31 points at 12 months (mean baseline score of 56.2, mean 6-month score of 30.7, and mean 12-month score of 25.1). The reviewers noted that there was significant variation across studies and between the types of implants used. With the 24-month and 36-month pain scores being specific to the iFuse and the HMA screws, respectively, it is difficult to draw conclusions from the analysis. The reviewers conceded that there was a paucity of high quality evidence for minimally invasive SIJF; with only one level I randomized trial and three prospective studies available. Other limitations included substantial variation across studies in both the follow-up interval and the types of outcome measures employed, which prohibited meta-analysis of certain variables and long-term outcomes. In addition, potential bias exists due to self-reporting of outcomes and retrospective study design of several of the included studies.

Noncomparative Studies

- In 2014, Rudolf and Capobianco published five-year clinical and radiographic outcomes on an industry-sponsored study of minimally invasive SIJF using iFuse implants in 21 consecutive patients diagnosed with degenerative sacroiliitis and/or sacroiliac joint disruptions.⁵³ Of 21 patients treated, 17 were available for five-year follow-up. Pain on VAS improved from 8.3 at baseline to 1.4 at 24 months ($p < 0.001$) and 2.4 at 60 months ($p = 0.001$). Mean ODI score at five years was 21.5 (SD 22.7), but five patients (29% reported severe to crippling disability). A qualitative review of x-ray and CT imaging on 15 patients (45 implants) showed increased bone density immediately adjacent to all implants, intra-articular osseous bridging in 87% of patients and no evidence of implant loosening or migration of the implants. Limitations of this study include small sample size, single site, single surgeon, self-reported outcomes and lack of control group.
- In 2015, Cher et al. published the results of an industry-sponsored implant survivorship analysis after minimally invasive SIJF using the iFuse implant system, including data from 11,388 cases of MIS SIJF implants performed between April 2009 and July 2014.⁵⁴ Four-year survivorship free from implant revision was reported at 96.46%. Revision rate did not differ by sex and was lower for age > 65 . In all, 24% of revisions occurred within the first 30 days after surgery; 63.5% occurred within the first year. The most common reasons for revision surgery were symptomatic malposition (SM) (38.4%) and symptom recurrence (SR) (47.6%). The majority (86.8%) of revisions for SM occur within the first six months, while most (87.9%) revisions for SR occur after month six. Implant survivorship has improved annually since the device was introduced in 2009, with 1-year revision rates of 9.7%, 4.9%, 2.0%, 1.8%, 1.5%, and 1.4% reported for 2009, 2010, 2011, 2012, 2013, and 2014, respectively ($p < 0001$).
- In 2016, Sachs et al. published a retrospective cohort study with a prospective evaluation component of patient-based outcomes after SIJF for chronic SIJ dysfunction due to degenerative sacroiliitis or SIJ disruption at a minimum of three years of follow-up including 107 consecutive patients.⁵⁵ This industry-sponsored study was conducted at seven U.S.-based centers, which were part of the clinical trials from the iFuse implants. At mean follow-up of 3.7 years, the mean SIJ pain

score was 2.6 (a 4.8-point improvement from baseline; $p < 0.0001$) and the mean ODI was 28.2, which is similar to the similar to 12-month ODI values observed in the INSITE RCT.⁴⁹ The ability to perform activities commonly impaired by SIJ dysfunction showed positive improvements in most patients. SIJ revision surgery was uncommon (five patients, 4.7%).

- In 2016, Duhon et al. published two year outcomes of an ongoing large prospective multicenter Sacroiliac Joint Fusion with iFuse Implant System® (SIFI) trial designed to evaluate the safety and effectiveness of the iFuse implants, inserted using the lateral approach, for the treatment of degenerative sacroiliitis, reporting on 172 patients at 26 US sites.⁵⁶ This study was an extension of the six-month outcomes published from the industry-sponsored. SIFI trial published in 2013.⁵⁷ Of the 194 patients enrolled to date, only 172 were available at 24-month follow-up. The primary reason for loss to follow-up is protocol noncompliance at one or more study centers, resulting in a loss of 15 patients to follow-up. The current loss to follow-up was 13.4% in this study.

The investigators reported that SIJ pain, as determined by self-reported VAS scores, decreased from 79.8 at baseline to 30.4 at 12 months and remained low at 26.0 at 24 months ($p < 0.0001$ for change from baseline). Disability, as measured by ODI, decreased from 55.2 at baseline to 31.5 at 12 months and remained low at 30.9 at 24 months ($p < 0.0001$ for change from baseline). The proportion of subjects taking opioids for SIJ or low back pain decreased from 76.2% at baseline to 55.0% at 24 months ($p < 0.0001$). Eight patients (4.7%) have undergone one or more revision SIJ surgeries and seven device-related adverse events occurred. At one-year post-implant, CT scan showed a high rate (97%) of bone adherence to at least two implants on both the iliac and sacral sides with modest rates of bone growth across the SIJ.

- In 2017, Dengler et al. published the results of a pooled analysis of two multicenter RCTs (INSITE and iMIA trials) and one multicenter single-arm prospective trial (SIFI) in order to identify predictors of outcomes of conservative and minimally invasive surgical management of SIJ pain.⁵⁸ Both the INSITE trial and the SIFI study only included patients with diagnosis of degenerative sacroiliitis or SI joint disruption, whereas the iMIA trial included a more heterogeneous population consisting of patients diagnosed with SI joint pain. A pooled analysis was deemed appropriate, as all three industry-sponsored trials were stated to have had insufficient sample sizes to perform analyses of predictors of treatment outcomes. The pooled analysis included 423 patients assigned to either nonsurgical management (NSM, $n = 97$) or SIJF using a lateral insertion technique ($n = 326$) in one of the three trials. The authors reported a reduction in SIJ pain was 37.9 points larger (95% confidence interval [CI] 32.5–43.4; $p < 0.0001$) in the SIJF group than in the NSM group. Similarly, the improvement in ODI was 18.3 points larger (95% CI 14.3–22.4), $p < 0.0001$ in the SIJF group. In NSM, no predictors of outcome were identified. In the SIJF group, reduced improvement in outcome was predicted by smoking ($p = 0.03$), opioid use ($p = 0.017$), lower patient age (> 59 years compared to < 24 years old, - 9.1 points difference; $p = 0.008$), and lower duration of SIJ pain ($p = 0.028$).

Of the 326 patients that underwent SIJF, 1.2% ($n = 4$) underwent early surgical revision due to implants inadvertently placed into a sacral neural foraminal, causing postoperative neuropathic symptoms and requiring surgical repositioning of the implant. Late revision surgery (> 1 month), performed in 2.8% ($n = 9$), was typically done to address ongoing pain, sometimes associated with poor implant position, with placement of additional implants in most cases. The authors acknowledged that both the iMIA and INSITE trials allowed crossover from nonsurgical to surgical

treatment after six months and therefore long-term outcomes for NSM cannot be evaluated. In addition, all three trials were unblinded, which could have confounded overall outcome results.

- In 2017, Bornemann et al. published the results of an independent case series designed to evaluate the safety and effectiveness of the iFuse implant system in 24 patients with SI joint syndrome in Germany.⁵⁹ VAS scores and ODI improved significantly immediately post- surgery from 84.3 ± 9.2 to 40.7 ± 9.2 and from 76.8 ± 9.2 to 40.7 ± 9.2 , respectively ($p < 0.001$). At 24-month follow-up, the ODI improved further to 31 ± 5.4 , whereas the VAS improved until 3 months post-procedure and then stayed constant up through the 24-month follow-up. No adverse events, intraoperative complications, implant malpositioning or loosening were reported.

Adverse Events & Contraindications

In 2020 Hayes published an evidence analysis research brief on the impact of cigarette smoking on spinal fusion outcomes.⁶⁰ The purpose of an evidence analysis is to consider whether or not there is sufficient evidence to conduct a health technology assessment. The Hayes authors identified a sufficient body of evidence to evaluate the impacts. Twelve studies of retrospective comparative design were retrieved, and a full-text review will follow in coming years.

LinQ (PainTeq) for Sacroiliac Joint Fusion

In 2020, ECRI published a review of the LinQ system's safety and efficacy for use during sacroiliac joint fusion. No relevant clinical utility studies were identified.

CLINICAL PRACTICE GUIDELINES

National Institute for Health and Care Excellence (NICE)

- In 2018, NICE published a medical technologies guidance on iFuse for treating chronic sacroiliac joint pain with the following recommendations:⁶¹
 - “The case for adopting the iFuse implant system to treat chronic sacroiliac joint pain is supported by the evidence. Using iFuse leads to improved pain relief, better quality of life and less disability compared with non-surgical management.
 - iFuse should be considered for use in people with a confirmed diagnosis of chronic sacroiliac joint pain (based on clinical assessment and a positive response to a diagnostic injection of local anaesthetic in the sacroiliac joint) and whose pain is inadequately controlled by non-surgical management.
 - Cost modelling indicates that...savings will increase over time. Savings will mainly come from fewer steroid joint injections and less pain relief medication with iFuse compared with non-surgical management.
- In 2017, NICE published an Interventional Procedures Guidance (IPG) on minimally invasive sacroiliac joint fusion surgery for chronic SI pain with the following recommendations:⁶²

- “Current evidence on the safety and efficacy of minimally invasive sacroiliac (SI) joint fusion surgery for chronic SI pain is adequate to support the use of this procedure ...
- Patients having this procedure should have a confirmed diagnosis of unilateral or bilateral SI joint dysfunction due to degenerative sacroiliitis or SI joint disruption.
- This technically challenging procedure should only be done by surgeons who regularly use image-guided surgery for implant placement. The surgeons should also have had specific training and expertise in minimally invasive SI joint fusion surgery for chronic SI pain.”

This IPG was evidence-based but was not based on a systematic review of the evidence. The evidence based evaluated for this guidance included two RCTs, two systematic reviews, three prospective cohort studies and two retrospective case series. Although the committee indicated MIS SIJF may be adequate, the committee noted a lack of long-term follow-up beyond three years. Lastly, the committee noted that, while this procedure achieves stabilization of the joint, there was evidence that fusion of the joint does not occur in many patients.

International Society for the Advancement of Spine Surgery (ISASS)

In 2016, the ISASS published a single-author policy statement on minimally invasive sacroiliac (SI) joint fusion.⁶³ This policy statement was evidence-based, but was not based on a systematic review of the evidence and did not report the methodology used to review the literature or if the evidence quality was formally assessed. The policy statement gave recommendations for MIS SI joint fusion; however, these recommendations are limited by a lack of supporting evidence.

North American Spine Society (NASS)

In 2015, the NASS published a coverage policy recommendation on percutaneous sacroiliac (SI) joint fusion.^{64,65} This policy statement was evidence-based, but did not report the methodology used to review the literature or if the evidence quality was formally assessed. The NASS guideline stated “(w)ithin the limits of a moderate body of evidence, the Coverage Committee recommends coverage for percutaneous SIJ fusion when the criteria outlined above are met. Due to the relatively moderate evidence, it is particularly critical that inclusion criteria are scrutinized and patient selection is executed with vigilance. The procedure itself has proven to be relatively safe.”

The criteria developed by the NASS committee are as follows:

Percutaneous (also referred to as minimally invasive) SIJ fusion (eg, insertion of a metallic device across the SIJ that is intended to fuse to the bone or lead to fusion of the joint itself, in distinction from insertion of screws without bone graft across the SIJ which are intended to stabilize but not fuse the joint) is indicated for the treatment of SIJ pain for patients with low back/buttock pain who meet ALL of the following criteria:

1. *Have undergone and failed a minimum 6 months of intensive nonoperative treatment that must include medication optimization, activity modification, bracing and active therapeutic exercise targeted at the lumbar spine, pelvis, SIJ and hip including a home exercise program.*
2. *Patient's report of typically unilateral pain that is caudal to the lumbar spine (L5 vertebra), localized over the posterior SIJ, and consistent with SIJ pain.*
3. *A thorough physical examination demonstrating localized tenderness with palpation over the sacral sulcus (Fortin's point, ie, at the insertion of the long dorsal ligament inferior to the posterior superior iliac spine or PSIS) in the absence of tenderness of similar severity elsewhere (eg, greater trochanter, lumbar spine, coccyx) and that other obvious sources for their pain do not exist.*
4. *Positive response to a cluster of 3 provocative tests (eg, thigh thrust test, compression test, Gaenslen's test, distraction test, Patrick's sign, posterior provocation test). Note that the thrust test is not recommended in pregnant patients or those with connective tissue disorders.*
5. *Absence of generalized pain behavior (eg, somatoform disorder) or generalized pain disorders (eg, fibromyalgia).*
6. *Diagnostic imaging studies that include ALL of the following:*
 - a. *Imaging (plain radiographs and a CT or MRI) of the SI joint that excludes the presence of destructive lesions (eg, tumor, infection) or inflammatory arthropathy that would not be properly addressed by percutaneous SIJ fusion.*
 - b. *Imaging of the pelvis (AP plain radiograph) to rule out concomitant hip pathology.*
 - c. *Imaging of the lumbar spine (CT or MRI) to rule out neural compression or other degenerative condition that can be causing low back or buttock pain.*
 - d. *Imaging of the SI joint that indicates evidence of injury and/or degeneration.*
7. *At least 75% reduction of pain for the expected duration of the anesthetic used following an image guided, contrast-enhanced intra-articular SIJ injection on 2 separate occasions.*
8. *A trial of at least one therapeutic intra-articular SIJ injection (ie, corticosteroid injection).⁶⁴*

Washington State Health Care Authority

In 2021, Washington State Health Care Authority published an updated evidence report on SIJF⁴⁰. The report concludes, "Among patients meeting diagnostic criteria for SI joint pain or dysfunction and who have not responded adequately to conservative management, minimally invasive SI joint fusion surgery is probably more effective than conservative management for reducing pain, improving function, improving quality of life at 6 months follow-up and at 1 to 2 years of follow-up, and is likely cost-effective though the certainty of this evidence varies from very low to moderate and varies by different follow-up timepoints. This evidence also suggests that adverse events up to 6 months are higher from minimally invasive SI joint surgery than conservative management, though the certainty of this evidence is very low. Minimally invasive SI joint fusion surgery may be more effective than open fusion for reducing pain and is associated with a shorter hospital length of stay, but the certainty of this evidence is very low. Based on evidence from uncontrolled studies, serious adverse events from minimally invasive SI joint surgery may be higher in usual practice compared to what is reported in RCTs. The incidence of revision surgery is likely no higher than 3.8% at 2 years. Limited evidence is available that compares open fusion to minimally invasive fusion or across different minimally invasive devices and procedures."

EVIDENCE SUMMARY

Open Sacroiliac Joint Fusion

Despite high complication rates and limited evidence, open sacroiliac joint fusion (SIJF) surgery has become a standard of care for the treatment of SI joint pain for specific conditions. These conditions include post-traumatic injury of the SI joint due to pelvic ring fracture/dislocation, infection/sepsis, sacral tumor, and spinal deformities. Open SIJF for SI joint pain due to causes other than those described above is not recommended due to an overall lack of evidence, prolonged intraoperative times, hospital stay, recovery time and high revision/reoperation rates.

Minimally Invasive/Percutaneous Sacroiliac Joint Fusion

Low-quality but consistent evidence suggests that minimally invasive sacroiliac joint fusion (SIJF) has the potential for increased pain relief, greater reduction in disability, improved patient function and quality of life for patients with chronic low back pain that is unresponsive to conservative nonsurgical management. While additional well-designed, long-term, randomized controlled are needed to further establish validity, four clinical practice guidelines from three bodies recommend the conditional use of minimally invasive SIJF in select patient populations.

BILLING GUIDELINES AND CODING

- For percutaneous arthrodesis of the sacroiliac joint with **transfixation device**, use 27279.
- For percutaneous arthrodesis of the sacroiliac joint by **intra-articular implant(s)**, use 0775T.
- For percutaneous arthrodesis of the sacroiliac joint using **both a transfixation device and intra-articular implant(s)**, use 0809T as of July 1, 2023 (*prior to* July 1, 2023, CPT instructed providers to use 27299).

CODES*		
CPT	27280	Arthrodesis, sacroiliac joint, open, includes obtaining bone graft, including instrumentation, when performed
	27279	Arthrodesis, sacroiliac joint, percutaneous or minimally invasive (indirect visualization), with image guidance, includes obtaining bone graft when performed, and placement of transfixing device
	0775T	Arthrodesis, sacroiliac joint, percutaneous, with image guidance, includes placement of intra-articular implant(s) (eg, bone allograft[s], synthetic device[s])
	0809T	Arthrodesis, sacroiliac joint, percutaneous or minimally invasive (indirect visualization), with image guidance, placement of transfixing device(s) and intraarticular implant(s), including allograft or synthetic device(s)
	22899	Unlisted procedure, spine

***Coding Notes:**

- The above code list is provided as a courtesy and may not be all-inclusive. Inclusion or omission of a code from this policy neither implies nor guarantees reimbursement or coverage. Some codes may not require routine review for medical necessity, but they are subject to provider contracts, as well as member benefits, eligibility and potential utilization audit.
- All unlisted codes are reviewed for medical necessity, correct coding, and pricing at the claim level. If an unlisted code is submitted for non-covered services addressed in this policy then it will be **denied as not covered**. If an unlisted code is submitted for potentially covered services addressed in this policy, to avoid post-service denial, **prior authorization is recommended**.
- See the non-covered and prior authorization lists on the Company [Medical Policy, Reimbursement Policy, Pharmacy Policy and Provider Information website](#) for additional information.
- HCPCS/CPT code(s) may be subject to National Correct Coding Initiative (NCCI) procedure-to-procedure (PTP) bundling edits and daily maximum edits known as “medically unlikely edits” (MUEs) published by the Centers for Medicare and Medicaid Services (CMS). This policy does not take precedence over NCCI edits or MUEs. Please refer to the CMS website for coding guidelines and applicable code combinations.

REFERENCES

1. Edemekong PF BD, Sukumaran S, et al.,. Activities of Daily Living (ADLs). <https://www.ncbi.nlm.nih.gov/books/NBK470404/>. Published 2020. Accessed 1/16/2023.
2. Lorio MP. Editor's Introduction: Update on Current Sacroiliac Joint Fusion Procedures: Implications for Appropriate Current Procedural Terminology Medical Coding. *International journal of spine surgery*. 2020;14(6):853-859.
3. Zaidi HA, Montoure AJ, Dickman CA. Surgical and clinical efficacy of sacroiliac joint fusion: a systematic review of the literature. *Journal of neurosurgery Spine*. 2015;23(1):59-66. <http://thejns.org/doi/pdf/10.3171/2014.10.SPINE14516>
4. Rudolf L. Sacroiliac Joint Arthrodesis-MIS Technique with Titanium Implants: Report of the First 50 Patients and Outcomes. *The open orthopaedics journal*. 2012;6:495-502.
5. iFuse Clinical Value Dossier. (SI-BONE). September 2017. <http://sibone.appdataroom.com/download/v/bde234c53f23d561d3c32ff0cacbf6566baa6a56336790?trackingGuid=AEA0C179-6FCE-4371-41EA-1631D16E190B>. Accessed 1/16/2023.
6. U.S. Food & Drug Administration (FDA). 510(k) Premarket Notification - iFuse Implant System® - iFuse-3D implant (K162733). 3/10/2017. <https://www.accessdata.fda.gov/scripts/cdrh/cfdocs/cfpmn/pmn.cfm?ID=K162733>. Accessed 1/16/2023.
7. U.S. Food & Drug Administration. 510(k) Premarket Notification. K151818. SImmetry® Sacroiliac Joint Fusion System. (Zyga Technology, Inc.). Approved 08/05/2015. <https://www.accessdata.fda.gov/scripts/cdrh/cfdocs/cfPMN/pmn.cfm?ID=K151818>. Accessed 1/16/2023.
8. Zyga. SImmetry® Sacroiliac Joint Fusion. <https://zyga.com/providers-doctors/simmetry-solution-sacroiliac-joint-dysfunction/>. Accessed 1/16/2023.
9. U.S. Food & Drug Administration. 510(k) Premarket Notification. K140079. Silex™ Sacroiliac Joint Fusion System. (X-spine Systems, Inc.). Approved 03/25/2014. <https://www.accessdata.fda.gov/scripts/cdrh/cfdocs/cfPMN/pmn.cfm?ID=K140079>. Accessed 1/16/2023.
10. CoreLink | Products | Minimally Invasive | Entasis®. <https://corelinksurgical.com/product/entasis/>. Accessed 1/16/2023.

11. U.S. Food & Drug Administration. 510(k) Premarket Notification. K152237. Entasis™ Dual-Lead Sacroiliac Implant. (CoreLink, LLC). Approved 02/04/2016.
<https://www.accessdata.fda.gov/scripts/cdrh/cfdocs/cfPMN/pmn.cfm?ID=K152237>. Accessed 1/16/2023.
12. Life Spine. SIMPACT® for SI Joint fixation. <https://lifespine.com/si-joint/>. Accessed 1/16/2023.
13. U.S. Food & Drug Administration. 510(k) Premarket Notification. SIMPACT Sacroiliac Joint Fixation System. Approved 12/15/2021.
<https://www.accessdata.fda.gov/scripts/cdrh/cfdocs/cfpmn/pmn.cfm?ID=K212903>. Accessed 1/16/2023.
14. U.S. Food & Drug Administration (FDA). 510(k) Premarket Notification. K170475. SICAGE™ System (Sicage LLC). Approved 05/05/2017. .
<https://www.accessdata.fda.gov/scripts/cdrh/cfdocs/cfPMN/pmn.cfm?ID=K170475>. Accessed 1/16/2023.
15. SICAGE. <http://sicage.omniwebdev.com/healthcare-professionals-sicage-system-overview/>. Accessed 1/16/2023.
16. Medtronic REIMBURSEMENT GUIDE for the Rialto™ SI Fusion System. 2016.
http://www.medtronic.com/content/dam/medtronic-com/products/spinal-orthopaedic/reimbursement/documents/PMD015389_5_0_Rialto_2017_Reimbursement_Guide_FY17.pdf. Accessed 1/16/2023.
17. U.S. Food & Drug Administration. 510(k) Premarket Notification. K161210. RIALTO™ SI Fusion System. (Medtronic). Approved 08/12/2016.
<https://www.accessdata.fda.gov/scripts/cdrh/cfdocs/cfPMN/pmn.cfm?ID=K161210>. Accessed 1/16/2023.
18. Camber Spine Technologies. Product page for Siconous SI Joint Fixation System.
<http://www.cambermedtech.com/siconous/>. Accessed 1/16/2023.
19. U.S. Food & Drug Administration. 510(k) Premarket Notification. K162121. Siconus™ SI Joint Fixation System. (Camber Spine Technologies). Approved 01/18/2017.
<https://www.accessdata.fda.gov/scripts/cdrh/cfdocs/cfPMN/pmn.cfm?ID=K162121>. Accessed 1/16/2023.
20. U.S. Food & Drug Administration. 510(k) Premarket Notification. Firebird SI Fusion System. Decision date, 11/18/2020.
<https://www.accessdata.fda.gov/scripts/cdrh/cfdocs/cfpmn/pmn.cfm?ID=K203138>. Accessed 1/16/2023.
21. Ledonio CG, Polly DW, Jr., Swiontkowski MF. Minimally invasive versus open sacroiliac joint fusion: are they similarly safe and effective? *Clinical orthopaedics and related research*. 2014;472(6):1831-1838.
22. ECRI. iFuse Implant System (SI-Bone, Inc.) for Minimally Invasive Sacroiliac Joint Fusion.
<https://www.ecri.org/components/ProductBriefs/Pages/24421.aspx>. Published 2022. Accessed 1/16/2023.
23. Smith AG, Capobianco R, Cher D, et al. Open versus minimally invasive sacroiliac joint fusion: a multi-center comparison of perioperative measures and clinical outcomes. *Annals of surgical innovation and research*. 2013;7(1):14.
<https://www.ncbi.nlm.nih.gov/pmc/articles/PMC3817574/>
24. Ledonio CG, Polly DW, Jr., Swiontkowski MF, Cummings JT, Jr. Comparative effectiveness of open versus minimally invasive sacroiliac joint fusion. *Medical devices (Auckland, NZ)*. 2014;7:187-193. <https://www.ncbi.nlm.nih.gov/pmc/articles/PMC4051734/>

25. Lingutla KK, Pollock R, Ahuja S. Sacroiliac joint fusion for low back pain: a systematic review and meta-analysis. *European spine journal : official publication of the European Spine Society, the European Spinal Deformity Society, and the European Section of the Cervical Spine Research Society*. 2016;25(6):1924-1931.
26. Inc. H. Open Sacroiliac Joint Fusion for Unspecified Sacroiliac Joint Dysfunction. Jun 22, 2017. ARCHIVED Jul 21, 2020. R. <https://evidence.hayesinc.com/report/htb.sacroiliac1348>. Accessed 1/16/2023.
27. Wise CL, Dall BE. Minimally invasive sacroiliac arthrodesis: outcomes of a new technique. *Journal of spinal disorders & techniques*. 2008;21(8):579-584. <https://www.ncbi.nlm.nih.gov/pubmed/?term=19057252>
28. McGuire RA, Chen Z, Donahoe K. Dual fibular allograft dowel technique for sacroiliac joint arthrodesis. *Evid Based Spine Care J*. 2012;3(3):21-28. <https://www.ncbi.nlm.nih.gov/pubmed/23532182>
29. Endres S, Ludwig E. Outcome of distraction interference arthrodesis of the sacroiliac joint for sacroiliac arthritis. *Indian journal of orthopaedics*. 2013;47(5):437-442. <https://www.ncbi.nlm.nih.gov/pmc/articles/PMC3796914/>
30. Fuchs V, Ruhl B. Distraction arthrodesis of the sacroiliac joint: 2-year results of a descriptive prospective multi-center cohort study in 171 patients. *European spine journal : official publication of the European Spine Society, the European Spinal Deformity Society, and the European Section of the Cervical Spine Research Society*. 2017. <https://rd.springer.com/article/10.1007%2Fs00586-017-5313-2>
31. Mason LW, Chopra I, Mohanty K. The percutaneous stabilisation of the sacroiliac joint with hollow modular anchorage screws: a prospective outcome study. *European spine journal : official publication of the European Spine Society, the European Spinal Deformity Society, and the European Section of the Cervical Spine Research Society*. 2013;22(10):2325-2331. <https://www.ncbi.nlm.nih.gov/pmc/articles/PMC3804714/>
32. Al-Khayer A, Hegarty J, Hahn D, Grevitt MP. Percutaneous sacroiliac joint arthrodesis: a novel technique. *Journal of spinal disorders & techniques*. 2008;21(5):359-363.
33. Khurana A, Guha AR, Mohanty K, Ahuja S. Percutaneous fusion of the sacroiliac joint with hollow modular anchorage screws: clinical and radiological outcome. *J Bone Joint Surg Br*. 2009;91(5):627-631. <https://www.ncbi.nlm.nih.gov/pubmed/19407297>
34. Kube RA, Muir JM. Sacroiliac Joint Fusion: One Year Clinical and Radiographic Results Following Minimally Invasive Sacroiliac Joint Fusion Surgery. *The open orthopaedics journal*. 2016;10:679-689. <http://www.ncbi.nlm.nih.gov/pmc/articles/PMC5220174/>
35. Buchowski JM, Kebaish KM, Sinkov V, Cohen DB, Sieber AN, Kostuik JP. Functional and radiographic outcome of sacroiliac arthrodesis for the disorders of the sacroiliac joint. *The spine journal : official journal of the North American Spine Society*. 2005;5(5):520-528; discussion 529. <https://www.ncbi.nlm.nih.gov/pubmed/?term=Functional+and+radiographic+outcome+of+sacroiliac+arthrodesis+for+the+disorders+of+the+sacroiliac+joint>
36. Schutz U, Grob D. Poor outcome following bilateral sacroiliac joint fusion for degenerative sacroiliac joint syndrome. *Acta orthopaedica Belgica*. 2006;72(3):296-308. <https://www.ncbi.nlm.nih.gov/pubmed/?term=Poor+outcome+following+bilateral+sacroiliac+joint+fusion+for+degenerative+sacroiliac+joint+syndrome>
37. Kibsgard TJ, Roise O, Stuge B. Pelvic joint fusion in patients with severe pelvic girdle pain - a prospective single-subject research design study. *BMC musculoskeletal disorders*. 2014;15:85. <https://www.ncbi.nlm.nih.gov/pmc/articles/PMC3995535/>

38. Beck CE, Jacobson S, Thomasson E. A Retrospective Outcomes Study of 20 Sacroiliac Joint Fusion Patients. *Cureus*. 2015;7(4):e260. <https://www.ncbi.nlm.nih.gov/pmc/articles/PMC4494528/>
39. Tran ZV, Ivashchenko A, Brooks L. Sacroiliac Joint Fusion Methodology-Minimally Invasive Compared to Screw-Type Surgeries: A Systematic Review and Meta-Analysis. *Pain physician*. 2019;22:29-40.
40. Washington State Health Care Authority. Sacroiliac joint fusion update. Final evidence report. May 17, 2021. <https://www.hca.wa.gov/assets/program/si-joint-fusion-update-final-report-20210517.pdf>. Accessed 1/16/2023.
41. Washington State Health Care Authority. Sacroiliac Joint Fusion - Final Evidence Report. 2018. <https://www.hca.wa.gov/assets/program/si-fusion-final-rpt-20181130.pdf>. Accessed 1/16/2023.
42. Dengler JD, Kools D, Pflugmacher R, et al. 1-Year Results of a Randomized Controlled Trial of Conservative Management vs. Minimally Invasive Surgical Treatment for Sacroiliac Joint Pain. *Pain Physician*. 2017;20(6):537-550. <http://www.painphysicianjournal.com/current/pdf?article=NDYwOQ%3D%3D&journal=107>
43. Polly DW, Swofford J, Whang PG, et al. Two-Year Outcomes from a Randomized Controlled Trial of Minimally Invasive Sacroiliac Joint Fusion vs. Non-Surgical Management for Sacroiliac Joint Dysfunction. *International journal of spine surgery*. 2016;10:28. <https://www.ncbi.nlm.nih.gov/pmc/articles/PMC5027818/>
44. Vanaclocha V, Herrera JM, Sáiz-Sapena N, Rivera-Paz M, Verdú-López F. Minimally Invasive Sacroiliac Joint Fusion, Radiofrequency Denervation, and Conservative Management for Sacroiliac Joint Pain: 6-Year Comparative Case Series. *Neurosurgery*. 2017:nyx185-nyx185. <http://dx.doi.org/10.1093/neuros/nyx185>
45. Stureson B, Kools D, Pflugmacher R, Gasbarrini A, Prestamburgo D, Dengler J. Six-month outcomes from a randomized controlled trial of minimally invasive SI joint fusion with triangular titanium implants vs conservative management. *European spine journal : official publication of the European Spine Society, the European Spinal Deformity Society, and the European Section of the Cervical Spine Research Society*. 2017;26(3):708-719.
46. ECRI Institute. Fuse Implant System (SI-Bone, Inc.) for Minimally Invasive Sacroiliac Joint Fusion. Published 5/20/2016. Updated 9/18/2019. <https://www.ecri.org/components/ProductBriefs/Pages/24421.aspx?tab=1#>. Accessed 1/16/2023.
47. Darr E, Cher D. Four-year outcomes after minimally invasive transiliac sacroiliac joint fusion with triangular titanium implants. *Medical Devices (Auckland, NZ)*. 2018;11:287.
48. Whang P, Cher D, Polly D, et al. Sacroiliac Joint Fusion Using Triangular Titanium Implants vs. Non-Surgical Management: Six-Month Outcomes from a Prospective Randomized Controlled Trial. *International journal of spine surgery*. 2015;9:6.
49. Polly DW, Cher DJ, Wine KD, et al. Randomized Controlled Trial of Minimally Invasive Sacroiliac Joint Fusion Using Triangular Titanium Implants vs Nonsurgical Management for Sacroiliac Joint Dysfunction: 12-Month Outcomes. *Neurosurgery*. 2015;77(5):674-690; discussion 690-671.
50. Vanaclocha V, Verdú-López F, Sánchez-Pardo M, Gonzalbes-Esterelles L. Minimally invasive sacroiliac joint arthrodesis: experience in a prospective series with 24 patients. *J Spine*. 2014;3(5).
51. Hayes Inc. Minimally invasive sacroiliac joint fusion using triangular titanium implants (iFuse Implant System, SI-Bone Inc.). . <https://evidence.hayesinc.com/report/dir.infuse3000>. Published 2022. Accessed 1/16/2023.
52. Heiney J, Capobianco R, Cher D. A systematic review of minimally invasive sacroiliac joint fusion utilizing a lateral transarticular technique. *International journal of spine surgery*. 2015;9:40.

53. Rudolf L, Capobianco R. Five-year clinical and radiographic outcomes after minimally invasive sacroiliac joint fusion using triangular implants. *The open orthopaedics journal*. 2014;8:375-383.
54. Cher DJ, Reckling WC, Capobianco RA. Implant survivorship analysis after minimally invasive sacroiliac joint fusion using the iFuse Implant System(®). *Medical devices (Auckland, NZ)*. 2015;8:485-492. <http://www.ncbi.nlm.nih.gov/pmc/articles/PMC4664491/>
55. Sachs D, Kovalsky D, Redmond A, et al. Durable intermediate-to long-term outcomes after minimally invasive transiliac sacroiliac joint fusion using triangular titanium implants. *Medical devices (Auckland, NZ)*. 2016;9:213-222.
56. Duhon BS, Bitan F, Lockstadt H, et al. Triangular Titanium Implants for Minimally Invasive Sacroiliac Joint Fusion: 2-Year Follow-Up from a Prospective Multicenter Trial. *International journal of spine surgery*. 2016;10:13. <http://www.ncbi.nlm.nih.gov/pmc/articles/PMC4852595/>
57. Duhon BS, Cher DJ, Wine KD, Lockstadt H, Kovalsky D, Soo C-L. Safety and 6-month effectiveness of minimally invasive sacroiliac joint fusion: a prospective study. *Medical devices (Auckland, NZ)*. 2013;6:219-229. <http://www.ncbi.nlm.nih.gov/pmc/articles/PMC3865972/>
58. Dengler J, Duhon B, Whang P, et al. Predictors of Outcome in Conservative and Minimally Invasive Surgical Management of Pain Originating from the Sacroiliac Joint: A Pooled Analysis. *Spine*. 2017;42(21):1664.
59. Bornemann R. RPP, Strauss A.C., Sander K., Rommelspacher Y., Wirtz D.C., Pflugmacher R. and Frey S.P. Two-year clinical trial results of patients with sacroiliac joint syndrome treated by arthrodesis using a triangular implant system. *Technol Healthcare*. 2016(25):319-325.
60. Hayes Inc. Impact of Cigarette Smoking on Spinal Fusion Outcomes. Nov 11, 2020. Archived Dec 11, 2021. <https://evidence.hayesinc.com/report/hss.smokingspinal4413>. Accessed 1/16/2023.
61. National Institute for Health and Care Excellence (NICE). iFuse for treating chronic sacroiliac joint pain. Published 10/2/3018. <https://www.nice.org.uk/guidance/mtg39>. Accessed 1/16/2023.
62. National Institute for Health and Care Excellence (NICE). Minimally invasive sacroiliac joint fusion surgery for chronic sacroiliac pain. Published date: 4/5/2017. <https://www.nice.org.uk/guidance/ipp578>. Accessed 1/16/2023.
63. International Society for the Advancement of Spine Surgery (ISASS). Policy Statement – Minimally Invasive Sacroiliac Joint Fusion. Updated July 5, 2016. <http://www.isass.org/public-policy/isass-policy-statement-minimally-invasive-sacroiliac-joint-fusion-july-2016/>. Accessed 1/16/2023.
64. North American Spine Society (NASS). Coverage Policy Recommendations - Percutaneous Sacroiliac Joint Fusion. November 1, 2015. <https://www.spine.org/Product-Details?productid=%7B9EAC3FC6-AF81-E611-851E-005056AF031E%7D>. Accessed 1/16/2023.
65. Wu PF, Li YW, Wang B, Jiang B, Tu ZM, Lv GH. Posterior Cervical Foraminotomy Via Full-Endoscopic Versus Microendoscopic Approach for Radiculopathy: A Systematic Review and Meta-analysis. *Pain Physician*. 2019;22(1):41-52.

POLICY REVISION HISTORY

DATE	REVISION SUMMARY
2/2023	Converted to new policy template.
5/2023	Added LinQ system to list of non-covered services.
7/2023	Q3 2023 code set update. Added CPT 0809T

